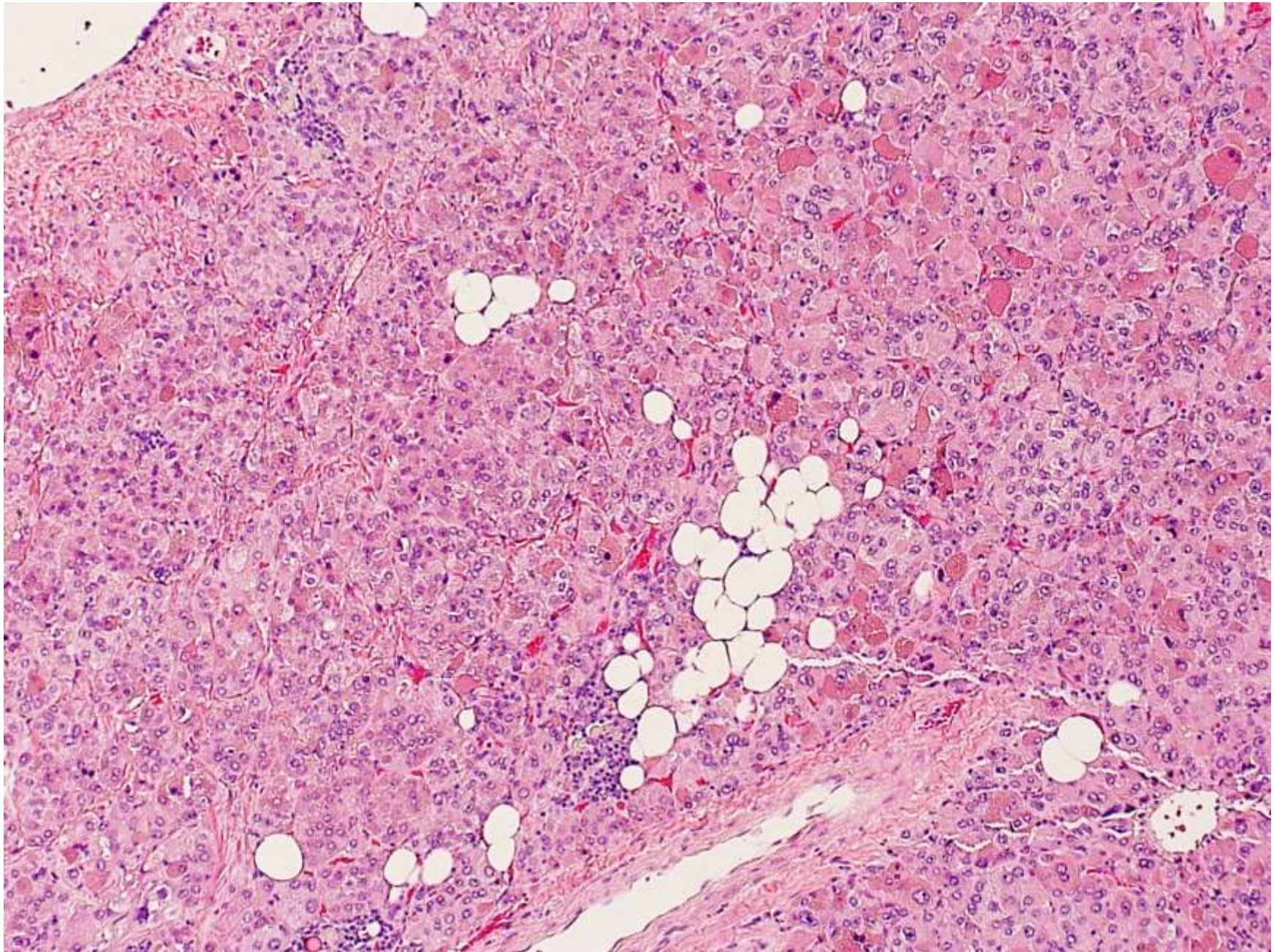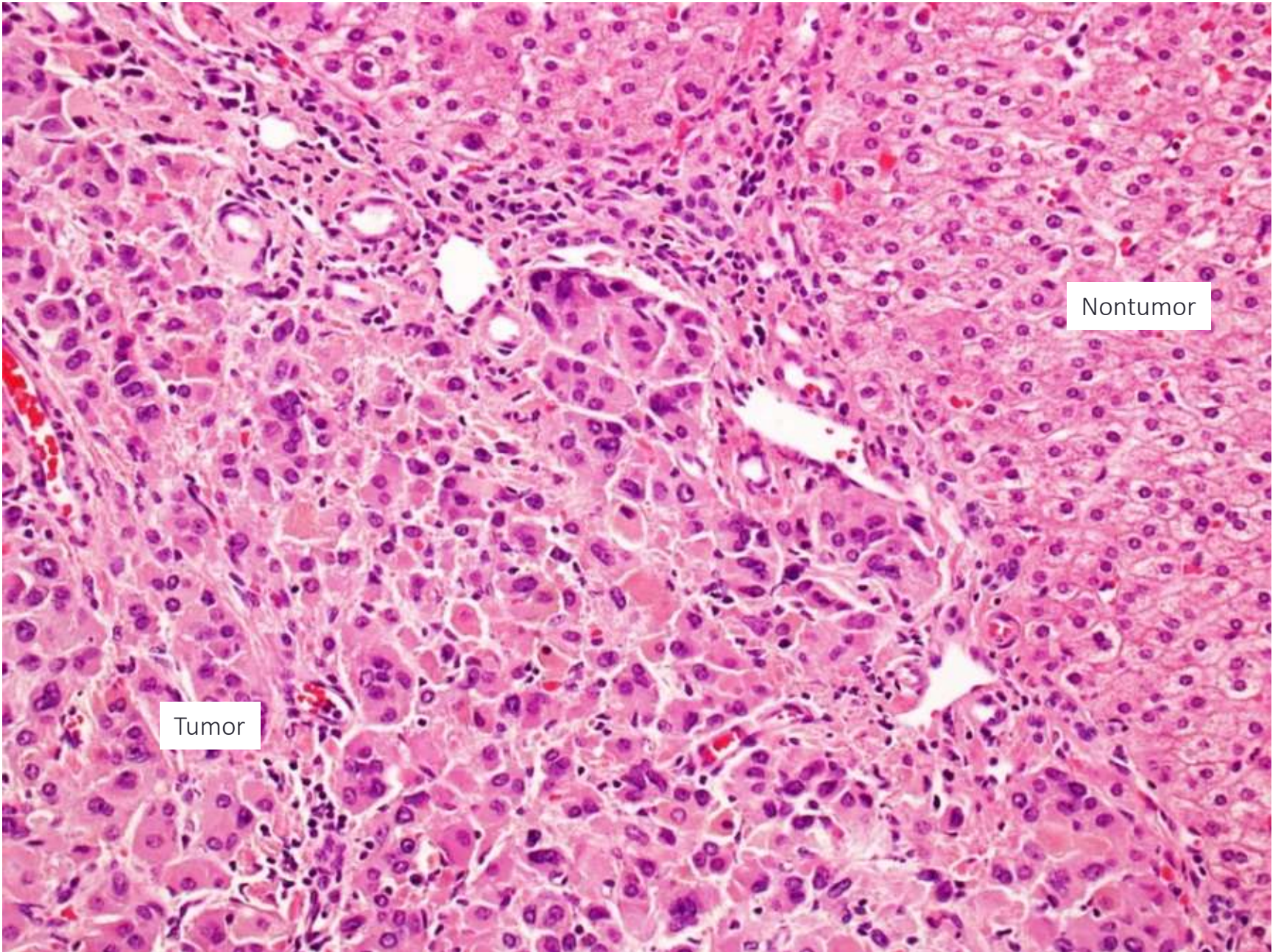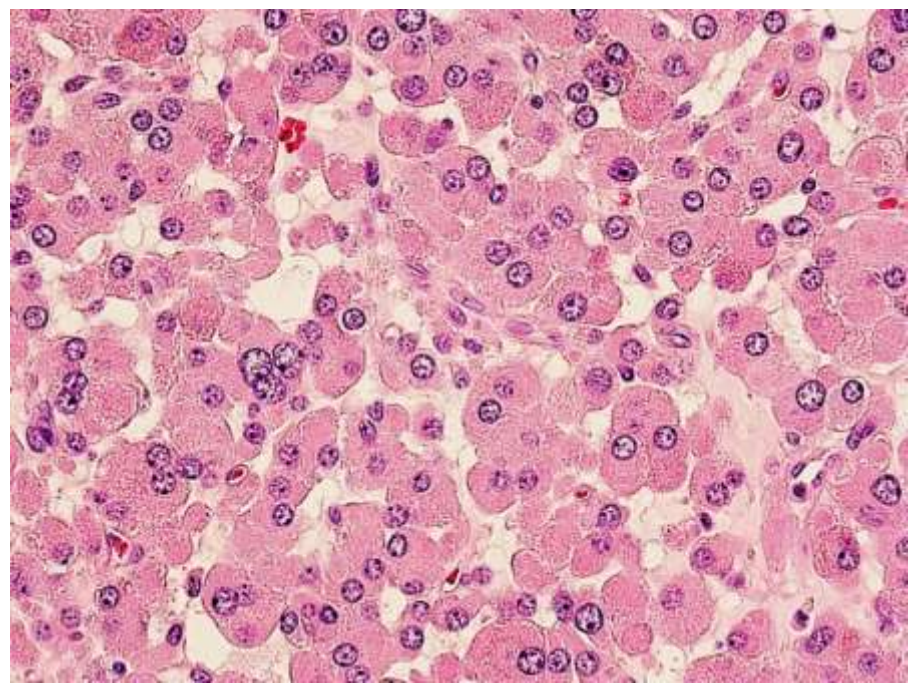
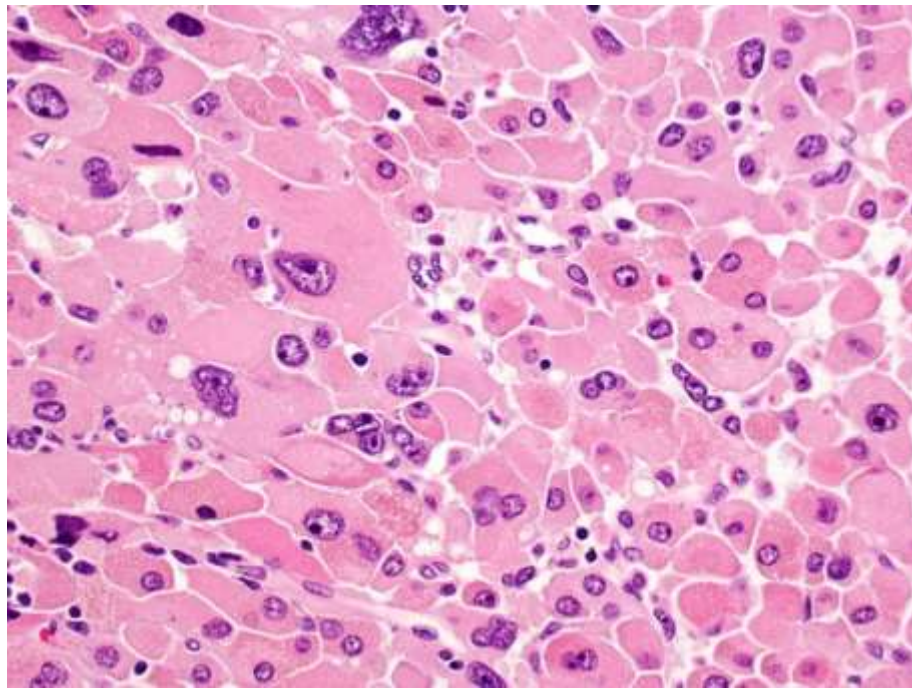
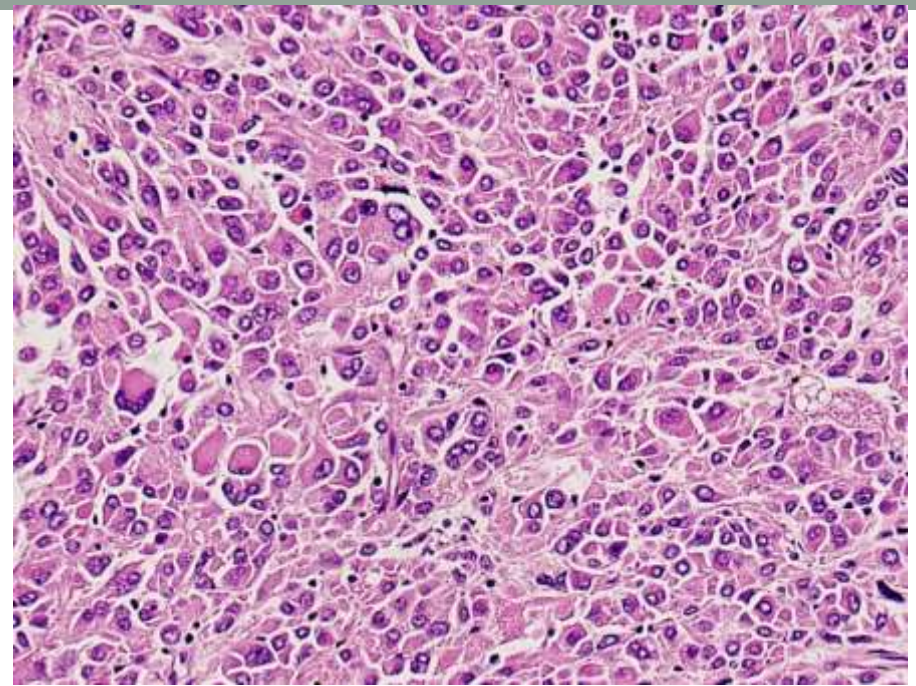
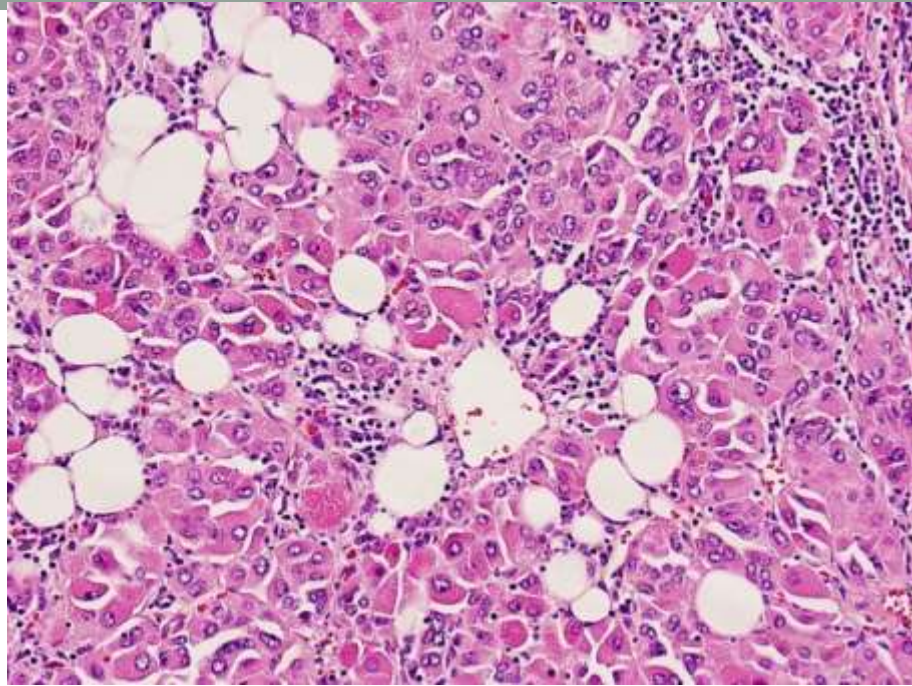


Tumor

Nontumor







## *Case 3 An Intrahepatic Mass*

- What patterns does the mass exhibit?
- What are your differential diagnoses?
- What immunohistochemical stains would you order?
- What more information would you ask for in the history and radiology?